



THE COLLEGE OF
OPTOMETRISTS

Stage Two

Overarching case scenario 65

AGE AND GENDER 78yrs, Female

ETHNIC BACKGROUND Caucasian

OCCUPATION AND HOBBIES Retired Cleaner Hobbies: Reading, TV, Gardening. Non-driver

PRESENTING SYMPTOMS AND HISTORY Has noticed a deterioration in reading vision over the past twelve months; thinks it may be because spectacle lenses scratched. Distance vision seems worse than last visit and difficult setting controls on central heating and microwave. Last eye examination 2 years ago when told, "some changes were going on at the back of eyes but nothing needed to be done as yet". Wears spectacles all day for both distance and reading.

GENERAL HEALTH AND MEDICATION Simvastatin taken.

PRESENT Rx, CENTRATION AND ACUITIES

CR39 Zeiss Gradal Top varifocals R +1.50 / -0.75 x 90 6/60 Add +2.50 N24 L +1.75 / -0.50 x 100 6/60 Add +2.50 N24

VISION R 3/60 N48 L 3/60 N48

REFRACTION R +1.25 / -0.50 x 90 Add +4.00 L +2.00 / -0.50 x 100 Add +4.00

VA Distance R 6/60 L 6/60 (pinhole worse R&L)

Near R N18 L N18

ACCOMMODATION Not measured

BINOCULAR STATUS D NMD N 4Δ XOP

MOTILITY Full with no discomfort

CONVERGENCE 10cm

PUPIL REACTIONS D,N,C full R & L. No RAPD

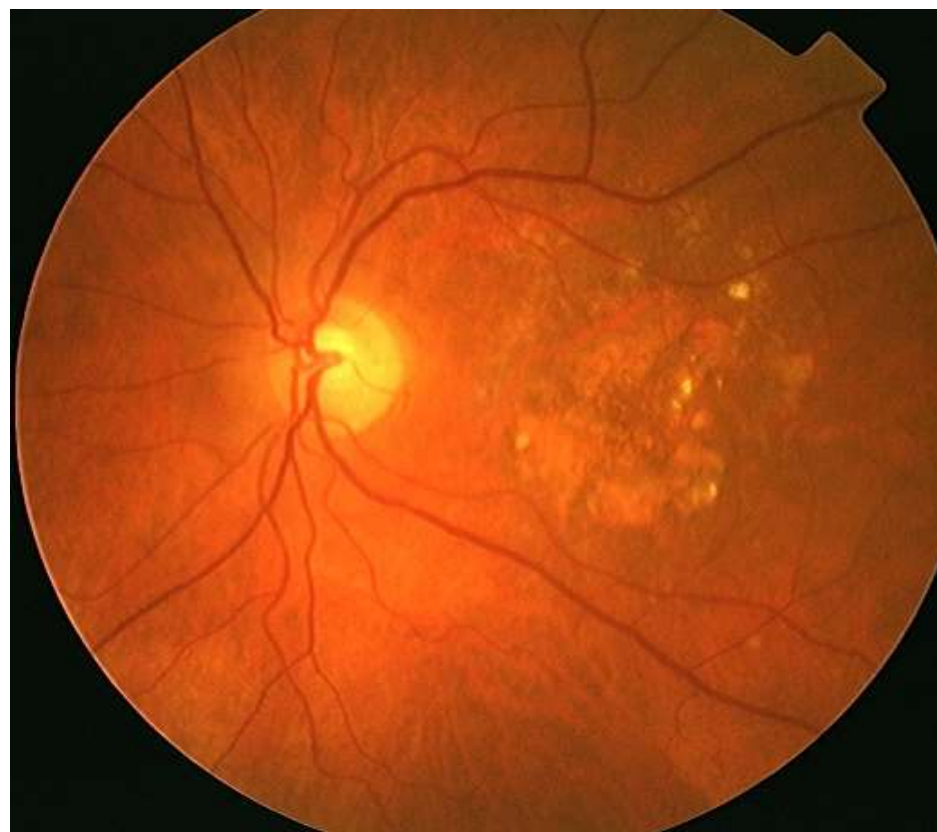
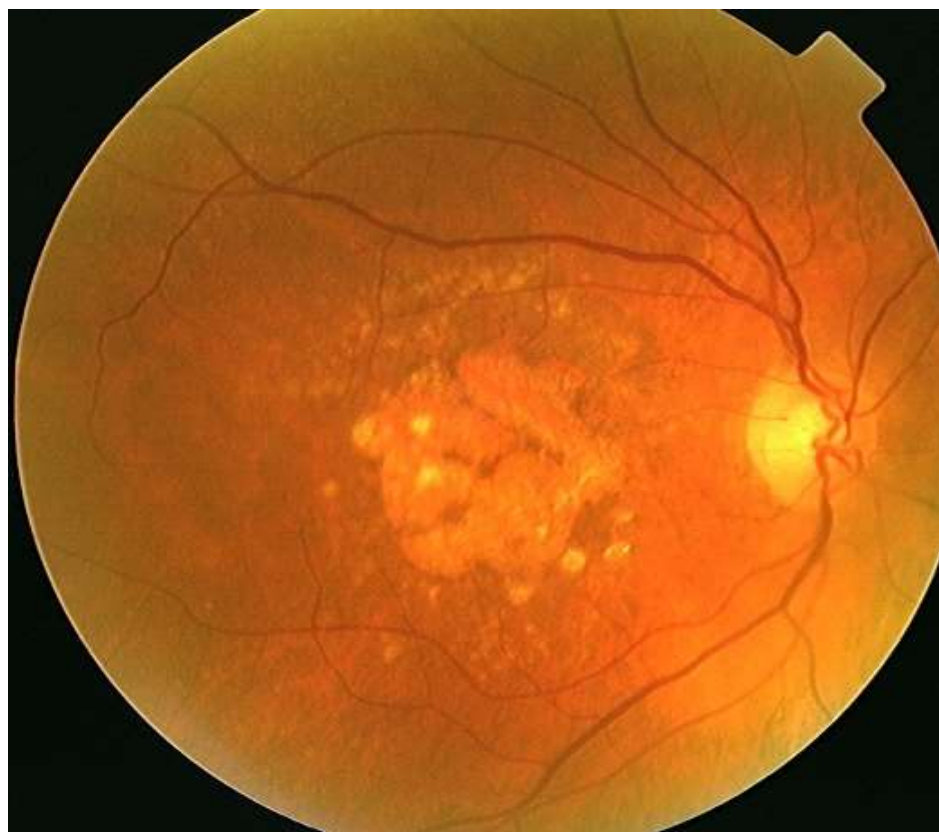
FUNDUS EXAMINATION See attached

FIELDS Unable to obtain reliable screener fields. Generally "not very clear" on Amsler – no scotoma identified

IOP R 12mmHg L 12mmHg @ 2.00pm Perkins

EXTERNAL EYE EXAMINATION See attached

Fundus Image



External Eyes

